Back Bone: The Spine Journal | April 2023-September 2023; 4(1): 09-13

Should 3D Navigation be the Standard of Care for MIS TLIF?

Bharat R. Dave[1], Ajay Krishnan[1], Devanand Degulmadi[1], Shivanand Mayi[1], Ravi Ranjan Rai[1], Mirant B. Dave[1]

Abstract

Introduction: Traditionally MIS TLIF is being performed under fluoroscopic guidance, which is technically difficult in few cases, often inaccurate and involves excessive radiation exposure to the surgeon and OR personnel. Navigation promises to be a better tool, however, literature regarding its accuracy is still evolving.

Aims & Objectives: To evaluate the pedicle screw perforation rate in Navigation guided MIS TLIF.

Materials and Methods: All consecutive patients undergoing MIS TLIF under 3D Navigation at single institute between January 2019 to January 2021 were included in the study. O-arm and S8 Stealth Navigation was used in all cases. After prone positioning and part preparation, patient tracker was fixed to a bony point nearest to the operative site, and then first CT scan spin was taken. Under Navigation guidance, all four guide wires were placed. Decompression was planned from the side which was more symptomatic. Screws on the opposite side were placed and connected with rod. Decompression was performed, and interbody cage was inserted from the symptomatic side, followed by insertion of remaining two screws under Navigation. A final CT scan spin was taken to determine the accuracy of hardware.

Results: 92 MIS TLIF were performed during the study period under 3D Navigation. 368 screws in 92 patients were analysed for accuracy. The direction and degree of breach was recorded. Four screws were found to breach, two were lateral breach, one superior breach and one medial breach. All breaches were Gr 1 and none of the screws required revision. Overall accuracy was 98.91 percent.

Conclusion: 3D Navigation is a useful tool in guiding placement of pedicle screws with high accuracy. This tool would be particularly indispensable in MISS cases, when tactile feedback is minimal.

Keywords: Surgical Navigation Systems, Computer-Assisted surgery, Minimally Invasive Surgical Procedures, Pedicle Screws.

Introduction

MIS TLIF is recognised as a standard procedure for lumbar fusion. It has been shown to have lesser blood loss, reduced post-operative pain and shorter hospital stay as compared to open TLIF [1]. Conventionally, this procedure has been carried out under C-arm. However, this involves significant radiation exposure to the surgeon as well as to the OT personnel [2]. Also, since there is no provision of tactile feedback in MIS TLIF, like feeling the pedicle walls with ball tip probe, the chances of pedicle breach may be higher [3, 4]; more so in cases with abnormal anatomy, like dysplastic narrow pedicle in high grade listhesis or degenerative scoliosis. The visualisation of S1 pedicle is particularly difficult with C-arm.

3D Navigation has a definitive advantage in this area over conventional C-arm. The image acquired is three dimensional. 3D Navigation can then be used to accurately target the pedicle screw through the pedicle, thereby increasing the accuracy and safety of the procedure and minimizing the complication rate.

We present a prospective, observational study of MIS TLIF performed under 3D Navigation, with an aim to analyse the safety and accuracy of placing pedicle screws.



[1]Department of Spine Surgery, Stavya Spine Hospital and Research Institute, Ahmedabad, Gujarat, India.

Address of correspondence :
Dr. Ravi Ranjan Rai,
Spine Surgeon, Department of Spine Surgery, Stavya Spine Hospital and Research Institute, Ahmedabad, Gujarat, India.
E-mail: drravirai84@gmail.com

Materials & Method

All consecutive patients, aged 18 and above, who underwent single level MIS TLIF under 3D Navigation, from January 2020 to January 2021, were included in the study. O-arm (Medtronic SN BI8021593) and Navigation (Medtronic S8 SN- N07534178) was used in all cases. Those patients with age less than 18, multilevel MIS TLIS, as well as those with

Submitted: 22/10/2022; Reviewed: 16/11/2022; Accepted: 11/01/2023; Published: 10/04/2023

Back Bone: The Spine Journal (The Official Journal Of "Spine Association of Gujarat") | Available on www.backbonejournal.com | DOI: https://doi.org/10.13107/bbj.2023.v04i01.053

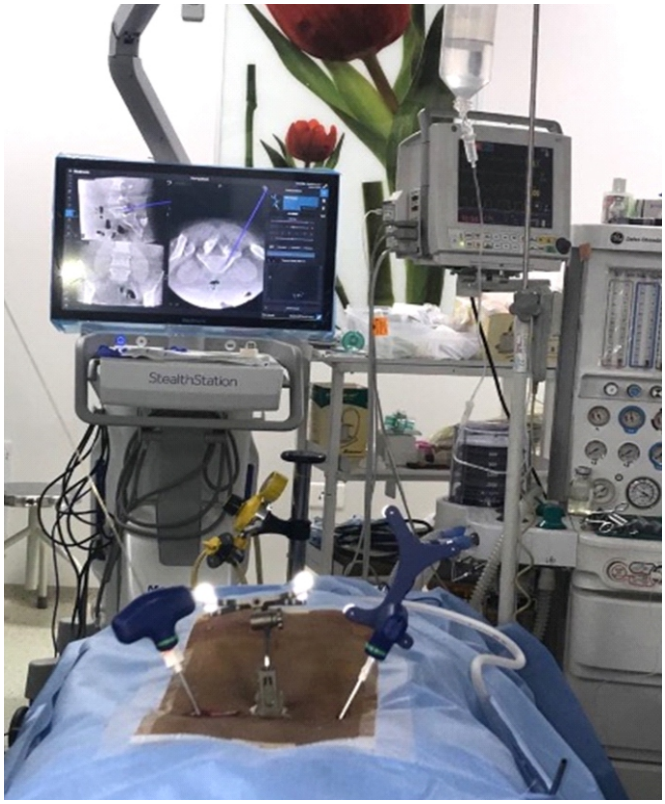

Figure 1: Shows operative site with Navigation frame attached and pilot hole being made with the PAK needle under Navigation guidance. Navigation screen is also visualised.

deformity, infection, trauma or tumour were excluded from the study. The demographic profile of patients is shown in Table 1. The indications of MIS TLIF were single level listhesis, degenerative stenosis, and lumbar disc herniation who have failed conservative management or present with progressive neurological deficit. Standard institutional protocol was followed for antibiotic prophylaxis and post-operative care. Patients were followed up at 6 weeks, 3 months, 6 months and 12 months from the date of surgery and PROMs were recorded.

Table 1: Demographic profile of the patients

	Number of patients
Total	92
Male/ Female	29/63
Mean Age	47.4
Level fused	
L3-4	12
L4-5	53
L5-S1	27
Indication of fusion	
Listhesis	61
Stenosis	12
Disc prolapse	19

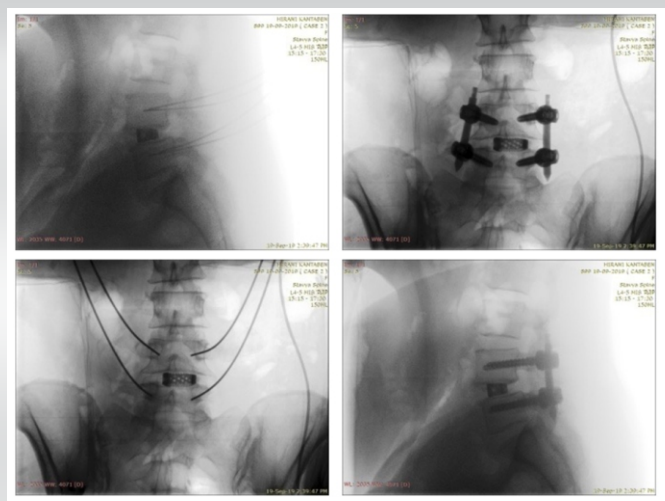

Figure 2: The images on the left are AP and lateral views after inserting cage and guidewire. The image on the right shows the final X-ray picture after TLIF.

Procedure

After induction, patient was positioned prone on a radiolucent OT table. We use four small, soft bolsters for prone positioning. After surgical site preparation, the incision was marked on the skin under 2D imaging. After skin incision, serial dilators were used to dock the tube over the facet joint on the side of radicular pain, and level checked again under imaging. Facetectomy and laminotomy was performed with the help of Ultrasonic bone scalpel and Kerrison punch. This helps us retain bone pieces which were used as bone graft, thereby eliminating the need to harvest additional bone graft or use bone substitutes. Neural decompression was accomplished as per plan. Over the top decompression, if indicated, was also completed at this stage. Then, discectomy was performed and disc space and end plate prepared with the help of end plate shavers and curettes. Adequate size cage was then inserted and cage position checked under 2D imaging. After this, the Navigation reference frame was fixed to the nearest bony point. In most cases, we used the subjacent spinous process. All the OT personnel were then instructed to leave the theatre and a CT scan spin was taken. The images thus acquired were transferred to the Navigation console. Then, under 3D Navigation, pedicle entry was taken with PAK (Pedicle Access Kit) needle, which was followed by insertion of guidewire over it, and then, insertion of navigated pedicle screws.

After insertion of all four screws under Navigation, a 2nd CT scan was taken in all the cases to ensure the accuracy of hardware placement. Pre-contoured rods were then inserted on either side through the jig and fixed with nuts. A final 2D image was taken to confirm the hardware position.

Results

92 MIS TLIF were performed during the study period under 3D Navigation. The post procedure CT scan of 92 patients were analysed for accuracy. Each of 368 screws were analysed in

Table 2: Showing results of the analysis.

	Number
Total screws analysed	368
Total number of screw breach	4
Grade of breach	
Grade 1	4
Grade 2	0
Grade 3	0
Grade 4	0
Direction of breach	
Medial	1
Lateral	2
Superior	1
Inferior	
Screws required revision	0
Mean Radiation exposure	48.6 mGy (+/- 19.2)
Mean duration of surgery	126 minutes (+/- 26)

Sagittal, axial and coronal planes to delineate the exact trajectory in order to identity and record any breach. The direction and degree of breach was recorded (Table 2). 4 screws were found to breach, two were lateral breach, one superior breach and one medial breach. All breaches were Gr 1 and none of the screws required revision. Overall accuracy was 98.91 percent. Average time take for the procedure was 126 (+/- 26) minutes. Average radiation exposure to the patient was measured as 48.6 (+/- 19.2) mGy.

Discussion

Achieving surgical goals while minimising the associated tissue damage has been the basic principle of surgical treatment. The advent of minimally invasive fusion techniques is an effort in the same direction. MIS TLIF has provided a more efficient method of achieving lumbar spine fusion, while reducing the blood loss, less muscle damage and shorter hospital stay as compared to open TLIF [1]. However, concerns remain regarding the accuracy of pedicle screw placement in MIS TLIF under fluoroscopy. Go Yoshida et al [3] concluded that minimal invasive method of pedicle screw insertion carries increased risk of inaccurate screw placement and suggested a technique of using oblique fluoroscopic views based on CT measurement. Kim et al [4], in their evaluation of 488 percutaneous pedicle screws, found a perforation rate of 11.1%, with two patients in their series requiring revision surgery for replacement of screws due to intractable pain and foot drop.

Another concern which remains with conventional pedicle screw fixation is cranial facet joint violation (FJV), which has been reported with both open as well as MIS techniques [5-7]. A screw placement found to be within one mm of facet joint on CT scan is considered to have FJV. Babu et al [6] found an overall higher grade of FJV and a greater incidence of high-grade violations among percutaneous procedures, as compared with open procedures. Park et al [7], in their series of 92 patients of MIS TLIF, reported an incidence of FJV as high as 50% of all patients and 31.5% of all screws. They found the incidence to be particularly higher at L5 level. Jones et al [8] also reported higher incidence of FJV in percutaneous group as compared with the open group. 3D Navigation promises to have the potential to allay these concerns regarding MIS TLIF procedure.

We are hereby sharing our experience of 368 screws in 92 patients who underwent MIS TLIF under 3D Navigation. All the pedicle screws put under Navigation were acceptable [9], with none of the screws requiring revision. The accuracy of pedicle screws under 3D Navigation in our study was 98.91 percent, which is at par with that reported with other similar studies.

Tarun Dusad et al [10] compared the navigated MIS TLIF against their own series of non-navigated MIS TLIF using C-arm based Navigation system. They found that the accuracy of pedicle screws in their study was 96.29% in navigated group while it was 91.67% in the non-navigated group. They reported significant reduction in radiation exposure to the patient in navigated group.

Xiaofeng Lian et al [11] described the use of Total 3D Navigation based MIS TLIF, thereby eliminating the need for fluoroscopy. They reported an accuracy rate of 98.6%. They used navigation for localization of the pathology, to plan the skin incisions, determining the size of the cage, cage placement, placement of screws and determine the size of rods. Several recent literatures have reinforced the accuracy of pedicle screw fixation using CT guided navigation or Robot assisted technology [12-15]. Weiner et al [16] in their narrative review emphasized that TLIF procedure is being replaced; from being fluoroscopic guided to 3D Navigation guided by intraoperative CT scan. They also underlined that most of the recent literature is concurrent to the fact that the use of image-guided navigation has helped in enhancing the accuracy of pedicle screw fixation while reducing the radiation exposure to the surgeon as well as the OT personnel.

A commonly stated concern, which surrounds the use of image guidance based on intra-operative CT scan, is regarding the radiation exposure to the patient. Eric Wang et al [17], presented a clinical review of 165 patients. They compared the radiation exposure and perioperative outcomes of patients undergoing open TLIF, fluoroscopy assisted MIS TLIF, intra-operative CT image guided navigation and Robot assisted TLIF. They concluded that radiation exposure was minimal in open TLIF (22.56 mGy), followed by intra-operative CT guided Navigation (50.21 mGy), followed by Robotic assisted TLIF (59.84 mGy) and maximum radiation exposure was observed in fluoroscopic MIS TLIF (82.02 mGy).

In the present study, our average radiation exposure to the patient has been 48.6 (+/- 19.2) mGy, which is much less than that seen in fluoroscopic guided MIS TLIF. This dose of radiation exposure is because we are taking 2nd CT scan spin at the end of the procedure to ensure accuracy of hardware placement. And inspite of this, the radiation exposure to the patient is less than fluoroscopy guided MIS TLIF. Additionally, it should be noted that in Navigation guided and Robotic assisted procedures, there is "no radiation exposure" to the surgeon or OT personnel, as against this, in fluoro-MIS procedures, the surgeon as well as the OT personnel get exposed to radiation. Funao et al [18] studied the radiation exposure to the surgeon during MIS TLIF procedures using fluoroscopy guidance. They concluded that the radiation exposure is higher in obese patients and that accumulated radiation exposure, particularly to surgeon's hands, should be carefully monitored.

Considering that use of intra-operative CT scan, alleviates the need for pre-operative CT scan, and that the overall radiation exposure to the patient in image guided 3D navigation is less than fluoroscopic assisted MIS TLIF, the concerns regarding the radiation exposure to the patient are ill founded.

Higher cost of enabling technology remains a challenge in its adoption and justifiability in low-income countries like. Dea et al [19] carried out an economic evaluation to compare the CT based navigation and fluoroscopic guided MIS TLIF. They concluded that CT based navigation has the potential to reduce the re-operation rate, thereby making it cost-effective, particularly at high-volume centres. This observation is supported by the present study, as there have been no re-operation in the present series. However, we do not have any cost-effectiveness analysis study specifically from low-income countries till date.

Conclusion

MIS TLIF is a time-tested procedure for treatment of lumbar degenerative disorders. CT based 3D Navigation is a safe method of placing pedicle screws more accurately, while reducing the radiation exposure to the surgeon, OT personnel as well as to the patient. Hence, 3D Navigation should be the standard of care for MIS TLIF.

References

[1] Tian NF, Xu HZ. Image-guided pedicle screw insertion accuracy: a meta-analysis. Int Orthop 2009; 33:895-903. 10.1007/s00264-009-0792.

[2] Nathaniel W. Jenkins, James M. Parrish, Evan D. Sheha, Kern Singh. Intraoperative risks of radiation exposure for the surgeon and patient. Ann Transl Med 2021;9(1):84.

[3] Go Yoshida, Koji Sato, Tokumi Kanemura, Toshiki Iwase, Daisuke Togawa, Yukihiro Matsuyama. Accuracy of Percutaneous Lumbosacral Pedicle Screw Placement Using the Oblique Fluoroscopic View Based on Computed Tomography Evaluations. Asian Spine J. 2016 Aug; 10(4): 630–638. Published online 2016 Aug 16.

[4] Kim MC, Chung HT, Cho JL, Kim DJ, Chung NS. Factors affecting the accurate placement of percutaneous pedicle screws during minimally invasive transforaminal lumbar interbody fusion. Eur Spine J 2011; 20:1635-43.

[5] Zhang Q., Xu Y. F., Tian W., et al. Comparison of superior-level facet joint violations between robot-assisted percutaneous pedicle screw placement and conventional open fluoroscopic-guided pedicle screw placement. Orthopaedic Surgery. 2019;11(5):850–856.

[6] Babu R, Park JG, Mehta AI, et al. Comparison of superior-level facet joint violations during open and percutaneous pedicle screw placement. Neurosurgery, 2012, 71: 962–970.

[7] Park Y, Ha JW, Lee YT, Sung NY. Cranial facet joint violations by percutaneously placed pedicle screws adjacent to a minimally invasive lumbar spinal fusion. Spine J, 2011, 11: 295–302.

[8] Jones-Quaidoo, S. M., Djurasovic, M., Owens, R. K., II, & Carreon, L. Y. (2013). Superior articulating facet violation: percutaneous versus open techniques, Journal of Neurosurgery: Spine SPI, 18(6), 593-597.

[9] Gertzbein SD, Robbins SE. Accuracy of pedicular screw placement in vivo. Spine (Phila Pa 1976) 1990; 15:11–4.

[10] Tarun Dusad, Vishal Kundnani, Shumayou Dutta, Ankit Patel, Gaurav Mehta, Mahendra Singh. Comparative Prospective Study Reporting Intraoperative Parameters, Pedicle Screw Perforation, and Radiation Exposure in Navigation-Guided versus Non-navigated Fluoroscopy-Assisted Minimal Invasive Transforaminal Lumbar Interbody Fusion. Asian Spine J 2018;12(2):309-316.

[11] Xiaofeng Lian, Rodrigo Navarro-Ramirez, Connor Berlin, Ajit Jada, Yu Moriguchi, Qiwei Zhang, and Roger Hartl. Total 3D Airo Navigation for Minimally Invasive Transforaminal Lumbar Interbody Fusion. BioMed Research International Volume 2016, Article ID 5027340, 8.

[12] Guan-yu Cui, Xiao-guang Han, Yi Wei, Ya-jun Liu, Da He, Yu-qing Sun, Bo Liu, Wei Tian.Robot-Assisted Minimally Invasive Transforaminal Lumbar Interbody Fusion in the Treatment of Lumbar Spondylolisthesis. Orthop Surg. 2021 Oct; 13(7): 1960–1968. Published online 2021 Sep 13.

[13] Shangju Gao, Jingchao Wei, Wenyi Li, Long Zhang, Can Cao, Jinshuai Zhai, Bo Gao. Accuracy of Robot-Assisted Percutaneous Pedicle Screw Placement under Regional Anesthesia: A Retrospective Cohort Study. Pain Res Manag. 2021; 2021: 6894001. Published online 2021 Dec 20.

[14] Yang J.-S., He B., Tian F., et al. Accuracy of robot-assisted percutaneous pedicle screw placement for treatment of lumbar spondylolisthesis: a comparative cohort study. Medical Science Monitor. 2019; 25:2479–2487. doi: 10.12659/msm.913124

[15] Kim H. J., Jung W. I., Chang B. S., Lee C. K., Kang K. T., Yeom J. S. A prospective, randomized, controlled trial of robot-assisted vs. freehand pedicle screw fixation in spine surgery. The international journal of medical robotics + computer assisted surgery: MRCAS.

2017;13(3).

[16] Joseph A. Weiner, Michael H. McCarthy, Peter Swiatek, Philip K. Louie, Sheeraz A. Qureshi. Narrative review of intraoperative image guidance for transforaminal lumbar interbody fusion. Ann Transl Med. 2021 Jan; 9(1): 89.

[17] Erik Wang, Jordan Manning, Christopher G. Varlotta, Dainn Woo, Ethan Ayres, Edem Abotsi, Dennis Vasquez-Montes, Themistocles S. Protopsaltis, Jeffrey A. Goldstein, Anthony K. Frempong-Boadu, Peter G. Passias, and Aaron J. Buckland. Radiation Exposure in Posterior Lumbar Fusion: A Comparison of CT Image-Guided Navigation, Robotic Assistance, and Intraoperative Fluoroscopy. Global Spine Journal 2021, Vol. 11(4) 450-457.

[18] Funao H, Ishii K, Momoshima S, Iwanami A, Hosogane N, et al. (2014) Surgeons' Exposure to Radiation in Single- and Multi-Level Minimally Invasive Transforaminal Lumbar Interbody Fusion; A Prospective Study. PLoS ONE 9(4): e95233.

[19] Nicolas Dea, MD, MSca, *, Charles G. Fisher, MD, MHScb , Juliet Batke, BScb , Jason Strelzow, MDb , Daniel Mendelsohn, MDb , Scott J. Paquette, MDb , Brian K. Kwon, MD, PhDb , Michael D. Boyd, MDb , Marcel F.S. Dvorak, MDb , John T. Street. Economic evaluation comparing intraoperative cone beam CT-based navigation and conventional fluoroscopy for the placement of spinal pedicle screws: a patient-level data cost-effectiveness analysis. The Spine Journal 16 (2016) 23–31.

Declaration of patient consent: The authors certify that they have obtained all appropriate patient consent forms. In the form, the patient has given his/her consent for his/her images and other clinical information to be reported in the Journal. The patient understands that his/her name and initials will not be published, and due efforts will be made to conceal his/her identity, but anonymity cannot be guaranteed.

Conflict of Interest: NIL
Source of Support: NIL

How to Cite this Article

Dave BR, Krishnan A, Degulmadi D, Mayi S, Rai RR, Dave MB | Should 3D Navigation be the Standard of Care for MIS TLIF? | Back Bone: The Spine Journal | April 2023-September 2023; 4(1): 09-13 | https://doi.org/10.13107/bbj.2023.v04i01.053