

Comparative Study between Anterior Cervical Discectomy and Fusion by Standalone Polyetheretherketone Cages and Tricortical Bone Graft with Anterior Plate Fixation for Cervical Spondylotic Myeloradiculopathy

Md. Anowarul Islam¹, Md. Shohidullah¹, Rumana Islam¹, Afia Ibnat Islam¹,
Abu Zaffar Chowdhury¹

Abstract

Background: Cervical spondylotic myeloradiculopathy is a common cause of neck pain and radiating arm pain. It develops when one or more of the intervening discs in the cervical spine starts to break down by wear and tear due to its degeneration. Multiple fixation modalities are used in Anterior Cervical Discectomy and interbody Fusion (ACDF), with their positive and negative sides

Objectives: The objective of the study is to compare the safety and efficacy of ACDF by standalone Polyetheretherketone (PEEK) cages with tricortical bone graft with anterior plate fixation for cervical spondylotic myeloradiculopathy.

Methods: This prospective observational study was conducted in the Department of Orthopaedics, Bangabandhu Sheikh Mujib Medical University, Dhaka from July 2017 to June 2020. Forty patients with cervical spondylotic myeloradiculopathy diagnosed on the basis of presenting complaints, clinical examination, and investigations were enrolled in this study. Modified Odom's criteria, visual analog scale (VAS), Nurick Grading, and Bridwell criteria for cervical spondylotic myelopathy was used for evaluation of the results.

Result: Male were predominant in this study. Male-female ratio was 2.9: 1. Most of the patients were farmer (30%), C5/6 (55%) was the most commonly involved disc level. Most of the patients had clinical features of neck pain, gait difficulty, and myelopathy sign. Regarding perioperative complications transient dysphagia was seen in 5 (12.5%) patients and transient paraparesis was observed in 2 (5%) patients. Post-operative complications were paresthesia and wound infection seen in significant number of patients of both groups who were recovered within 3–6 months. According to Bridwell's grade of fusion, Grade I fusion was observed in 16 patients (80%) in cage group and 18 patients (90%) in tricortical Indocyanine Green (ICG) with plate group. According to VAS, postoperatively pain was gradually decline and after 12 months, 12 patients (60%) patients were found in no pain group and 11 patients (55%) were found in no pain group of the tricortical ICG with plate group. There was no significant difference between the two groups ($P = 0.04$). According to modified Odom's criteria functional outcome after 12 months was excellent in 18 patients (90%) and good in 2 patients (10%) in cage group and excellent in 17 patients (85%) and good in 3 patients (15%) in tricortical ICG with plate group. There was no statistically significant difference between two groups ($P = 0.432$).

Conclusion: ACDF is the ideal technique for the treatment of cervical spondylotic myeloradiculopathy with excellent functional outcome and good fusion which could be achieved by either standalone PEEK cage or tricortical ICG with plate and there is no significant difference between two techniques.

Keywords: Cervical spondylotic myeloradiculopathy, Tricortical bone graft, Anterior cervical discectomy and fusion.

**BACK
BONE**
THE SPINE JOURNAL

¹Department of Orthopaedics, Bangabandhu Sheikh Mujib Medical University, Dhaka, Bangladesh.

Address of correspondence :

Dr. Anowarul Islam,
Department of Orthopaedics, Bangabandhu Sheikh Mujib Medical University, Dhaka, Bangladesh.
E-mail: maislam.spine@gmail.com

Introduction

Cervical myelopathy is a disease involving cervical vertebrae. When cervical myelopathy occurs as a result of spondylosis, it is referred to as cervical spondylotic myelopathy. Cervical spondylotic Patients present with a various findings, including clumsiness, loss of manual function, difficult gait or balance, urinary problem, motor weakness, sensory changes, and abnormal or pathologic reflexes [1].

Submitted: 4/7/2021; Reviewed: 12/8/2021; Accepted: 25/9/2021; Published: 10/10/2021

Back Bone: The Spine Journal (The Official Journal Of "Spine Association of Gujarat") | Available on www.backbonejournal.com | DOI:10.13107/bbj.2021.v02i02.025
This is an Open Access article distributed under the terms of the Creative Commons Attribution Non-Commercial-Share Alike 4.0 License (<http://creativecommons.org/licenses/by-nc-sa/4.0>) which allows others to remix, tweak, and build upon the work non-commercially as long as appropriate credit is given and the new creation are licensed under the identical terms.

The circumferential compression due to spondylosis leads to spinal cord compression and a static impingement on the spinal cord. [2]. Cervical motion and instability can cause pinching of the spinal cord between the anterior chondro-osseous spurs and the posterior ligamentous components [3].

The pathophysiology of cervical spondylotic myelopathy has multifactorial causes [4]. With increasing age, the intervertebral discs desiccate, flavum hypertrophied resulting in loss of disc height [5].

Anterior cervical discectomy and fusion (ACDF) is surgical procedure for treating cervical spondylotic myeloradiculopathy. Classically, spinal fusion was obtained by means of iliac crest autograft where tricortical bone graft harvesting causes donor site morbidity in up to 30% of patients, the use of cage gained great popularity among surgeons in recent years. Physical characteristics of polyetheretherketone (PEEK) cages improve spinal fusion whereas iliac crest autograft for single or multilevel ACDF was found to be associated with higher fusion and significantly lower costs compared with cages, PEEK cages, standalone PEEK cages, or other implants. [6].

Interbody fusion provides spine surgeon the ability to decrease abnormal painful motion in the spine. Recent treatments confirm that that fusion is the ideal treatment in cervical PID. Several modalities of surgery for performing ACDF such as Cloward technique, Smith Robinson technique, Bailey/Badgley technique. Autograft and allograft along with different cages are used for fusion. If the graft is used alone without any cage, it could be collapsed, extruded and there could be pseudoarthrosis. Cervical miniplate and screw are used to achieve further stability [7].

The goal of surgery is to decompress the cord and nerve roots while providing a stability and to restore alignment. ACDF using iliac crest autograft is the gold standard with excellent functional outcome. However, donor site morbidity is a concern with the use of iliac crest autograft. Standalone PEEK cages have been emerged as the implant of choice for interbody fusion in ACDF [8].

Methods and Materials

The study was carried out at the Department of Orthopaedic Surgery at Bangabandhu Sheikh Mujib Medical University, Shahbag, Dhaka from July 2017 to June 2020. A total of 40 patients were included in the study. Patients with Progressive spinal cord compression due to cervical spondylotic myeloradiculopathy, motor weakness in the upper and lower extremities. After taking informed consent, detailed history and physical examination of each patient was performed. Plain radiographs and MRI of the cervical spine were performed in all patients. All necessary investigations for surgery were performed before operation. Patients were allocated into two

groups by purposive randomized sampling methods. One group received standalone PEEK cage and other group received tricortical Indocyanine Green (ICG) with plate. Outcome is measured using visual analog score (VAS) for pain, Nurick Grading for neurological, Bridwell criteria for radiological fusion. Final overall improvement was evaluated by Modified Odom's criteria. The results were expressed as percentage and mean \pm SD and $p < 0.05$ was considered as the level of significant.

Surgical procedure

Patient in the supine position. Tong traction applied. A sandbag was applied in the interscapular area. Transverse skin incisions over the targeted vertebral level were made. The platysma incised. The esophagus retracted medially, and

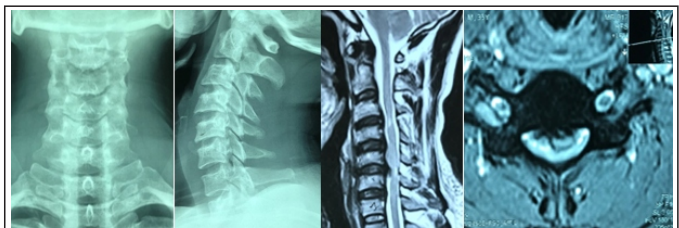

Figure 1: Preoperative X-ray and magnetic resonance imaging of the cervical spine showing disc space reduction in C5/6 and prolapse of C5/6 disc causing compression to the spinal cord with myelomalacic change.

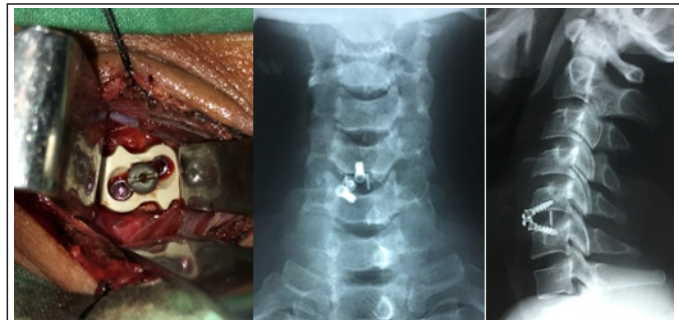

Figure 2: Intraoperative image and post-operative X-ray showing placement of standalone polyetheretherketone cage with a screw.

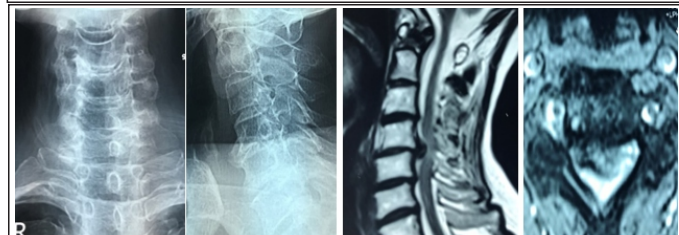


Figure 3: Pre-operative X-ray of cervical spine A/P and lateral view and magnetic resonance imaging of the cervical spine.

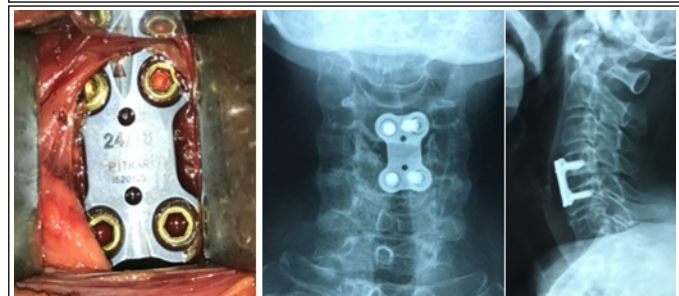

Figure 4: Intraoperative picture with postoperative X-ray showing plate fixation.

sternocleidomastoid with underlying carotid sheath was retracted laterally. The prevertebral fascia was divided, longus colli muscle retracted. Intraoperative radiographs were obtained by image intensifier to confirm the appropriate cervical level. The offending disc was removed with a rongeur and osteophytes were removed from the posterior aspect of the vertebral body. The vertebral body endplates was decorticated. Then for standalone PEEK cage, cage inserted and fixed with a screw. For the bone graft group, bone graft harvested, and fixed. Plate fixation was done. Wound was closed by layers. Sterile dressing was given and cervical orthosis was applied before extubation. The donor area was closed layer by layer and sterile dressing was applied.

Results

Most of the patients were found in the age of 51–60 years, 18 patients (45%), 15 patients (37.5%) were seen in the age group 41–50 years, 5 patients (12.5%) were found in the age group ≤40 years, 2 patients (5%) were found in the age group ≥60 years. Mean age of the patients was 48.6 ± 7.42 years.

Twenty-nine patients (72.5%) were male and 11 patients (27.5%) were female. Male-female ratio was 2.9:1. Most of the patients were farmers 12 (30%), housewife 10 (25%), business 8 (20%), daylabor 7 (17.5%), and service man 3 (7.5%).

Most commonly involved disc level was C5/6 (55%), then, respectively, C6/7, C4/5 and C3/4 disc level. In the cage group, 12 patients (60%) were found in the C5/6 level, and in the tricortical ICG group 10 patients (50%) were found in the C5/6 level of disc space.

Transient dysphagia was seen more in the tricortical bone graft group. 5 (12.5%) patients were suffering from transient dysphagia among them two patients (10%) in cage group and three patients (15%) in the tricortical ICG group. Transient paraparesis was developed in 2 (10%) patients among them one patient (5%) in the cage group and 1 patient (5%) in the tricortical ICG group who were recovered within very short period. Damage to the dura was not observed. Post-operative paresthesia developed in 2 patients (10%) in 1 month in cage group and 2 patients (10%) in 1 month in the tricortical bone graft group who were recovered within 2 months. Bone graft donor site pain developed in 5 patients (25%) in 1 month and 2 patients (10%) in 3 months seen only in tricortical bone graft with plate group. Wound infection was seen in 1 patient (5%) in 1 month seen only in tricortical bone graft with plate group.

According to VAS, among the 40 patients pre-operatively 17 patients (42.5%) with a painful state level – 7, 13 patients (32.5%) with painful state level – 6 and 6 patients (15%) with painful state level 5 and 4 patients (10%) with painful state level 9. Post-operatively pain was gradually decline and at 12 months 12 patients (60%) were found in none pain level and 7 patients (35%) found in level 1 and 1 patient (5%) was found in pain state level 2 of the cage group and 11 patients (85%) were found in none pain level, 8 patients (40%) found in pain level 1 and 1 patient (5%) was found in pain level 2 of the tricortical ICG with plate group.

According to Nurick grading, out of 40 patients pre-operatively 35 patients (87.5%) found in Grade 3 level, and 5 patients (12.5%) found in grade 4 level. Post-operatively at 12 months in standalone PEEK cage group 18 patients (90%) excellent and 2 patients (10%) good. In tricortical ICG group 16 patients (80%) excellent, 3 patients (15%) good, and 1 patient (5%) fair.

According to Bridwell grade of fusion, Grade I fusion was observed in 16 patients (80%) in 12 months in standalone PEEK cage group and 18 patients (90%) in 12 months in tricortical bone graft with plate group. Grade of fusion was more in tricortical bone graft with plate group. The difference between these groups was not statistically significant (P = 0.007).

According to modified Odom’s criteria (Table 1) on post-operative outcome – at 12 months of follow up 18 patients (90%) showed excellent, two patients (10%) showed good outcome in standalone PEEK cage group and 17 patients (85%) showed excellent and 3 patients (15%) showed good outcome in tricortical bone graft with plate group. Poor and fair outcome was not found.

Discussion

Most of the patients were found in the age group 51–60 years and 10 patients (50%) were in standalone PEEK cage group and eight patients (40%) were found in the tricortical bone graft group. Male was predominant in this study. Male were 29 (72.5%) and female were 11 (27.5%) in number.

In this study, most of the patients were farmers (30%) then housewife (25%), businessman (20%), day labor (17.5%), and serviceman (7.5%). Among the 12 patients of farmer group 8 patients (40%) in the standalone PEEK cage group and 4 patients (20%) in the tricortical ICG group. Farmers are generally carrying weight on the head. Islam et al., 2012 showed sedentary workers (43.75%), heavy worker (18.75%), and housewife (37.5%) [12].

In this study, highest number of disc space involvement intervertebral was in the level of C5/6 (55%). Among that level of involvement, 12 patients (60%) in standalone PEEK cage

Table 1: Distribution of study subjects according to modified Odom’s criteria (n=40; n1=20 and n2=20)

Grading	Standalone PEEK Cage group ₁ (%)				Tricortical ICG with plate group ₂ (%)				P value
	1 month n ₁ (%)	3 month n ₁ (%)	6 month n ₁ (%)	12 month n ₁ (%)	1 month n ₂ (%)	3 month n ₂ (%)	6 month n ₂ (%)	12 month n ₂ (%)	
Excellent	9 (45%)	12 (60%)	15 (75%)	18 (90%)	7 (35%)	10 (50%)	12 (60%)	17 (85%)	0.0432
Good	7 (35%)	5 (25%)	3 (15%)	2 (10%)	7 (35%)	7 (35%)	7 (35%)	3 (15%)	
Fair	4 (20%)	3 (15%)	2 (10%)	0 (0.0)	6 (30%)	3 (15%)	1 (5%)	0 (0.0)	
Poor	0 (0.0)	0 (0.0)	0 (0.0)	0 (0.0)	0 (0.0)	0 (0.0)	0 (0.0)	0 (0.0)	

group and 10 patients (50%) in the tricortical ICG group. Abdullah et al. 2016 showed in their study highest number of patients in the level of C5/6 and among them 1 patient (8.3%) in the cage group and 4 patients (33.3%) in the plate group [13]. Ayman et al. 2013 showed that regarding the levels operated; there were 14 patients in C3/4 level, 18 patients in C4/5 level, 26 patients in C5/6 level, and four patients in C6/7 level. All these are similar to our study [14].

Regarding perioperative complications, in our study transient dysphagia was seen in 5 patients (12.5%) and transient paraparesis in 2 patients (10%) who were recovered within very short period. Two patients (10%) in standalone PEEK cage group and 3 patients (15%) in tricortical ICG group were suffering from transient dysphagia. One patient (5%) in standalone PEEK cage group and 1 patient (5%) in the tricortical ICG group were suffering from transient paraparesis. Ayman et al. 2013 stated that there were some transient complications; dysphagia was reported in 5 patients (12.5%) which was improved within the first 2 weeks [14]. Islam et al. 2016 stated that in their study dysphagia was reported in 4 patients (13.3%) which was improved after 3 weeks [7]. Paresthesia developed in 2 patients (10%) in 1 month in standalone PEEK cage group and 2 patients (10%) in 1 month in the tricortical bone graft group who were recovered within 2 months. Bone graft donor site pain developed in 5 patients (25%) in 1 month and 2 patients (10%) in 3 months seen only in tricortical bone graft with plate group. Wound infection was seen in 1 patient (5%) in 1 month seen only in tricortical bone graft with plate group. Islam et al. 2016 stated that SSI in graft site reported in 1 patient (3.3%) [7].

According to VAS among the 40 patients preoperatively 17 patients (42.5%) with painful state level – 7, 13 patients (32.5%) with painful state level – 6, 6 patients (15%) with painful state level 5 and 4 patients (10%) with painful state level 9. and 10 patients (25%) with painful state level 7 and 6. Post-operatively pain was gradually decline at 12 months 12 patients (60%) were found in none pain level and 7 patients (35%) found in level 1 and 1 patient (5%) was found in pain state level 2 of the standalone PEEK cage group. 11 patients (55%) were found in none pain level, 8 patients (40%) found in pain level 1, and 1 patient (5%) was found in pain level 2 of the tricortical ICG with plate group.

According to Nurick grading – out of 40 patients preoperatively 35 patients (87.5%) found in grade 3 level and 5 patients (12.5%) found in grade 4 level. Post-operatively at 12 month in standalone PEEK cage group 18 patients (90%) in grade 0 level (excellent) and 2 patients (10%) in grade 1 level (Good). In the tricortical ICG group 16 patients (80%) in grade 0 level (excellent), 3 patients (15%) in grade 1 level (Good) and 1 patient (5%) in grade 2 level (Fair). The difference between these two groups was not statistically

significant ($P = 0.0525$). Islam et al. 2016 described that significant post operative improvement was recorded after 24 months by the Nurick scale 93% were excellent in the PEEK cage group and 86% in the ICG group. Statistically it was not significant between two groups p value < 0.35 [7]. Smith and Robinson, 1958 outcome obtained as excellent in 64.2%, good in 14.2%, fair in 14.2%, and poor in 7.1%. As a whole satisfactory outcome was 78.4% [16].

According to Bridwell grade of fusion, Grade I fusion was observed in 16 patients (80%) at 12 months in standalone PEEK cage group and 18 patients (90%) at 12 months in tricortical ICG with plate group. Bony fusion was more in tricortical ICG group than cage group. Islam et al., 2016 stated in their study that fusion occurred in 13/15 patients (86%) segments of the PEEK group, while it was 14/15 (93.3%) of the ICG group segments [7]. Ayman et al. 2013 stated that fusion occurred in 17/20 patients (85%) and 29/34 (85.2%) segments of the PEEK group, while it was 18/20 patients (90%) and 25/28 (85.2%) segments of the ICG group [14]. Lee et al. 2018 stated that fusion status of the final follow-up was 94.1% in the allograft group, which showed 16 out of 17 patients had achieved union. In the autograft group, 23 out of 24 patients had achieved union with a fusion rate of 95.7%. Fusion status was not significantly different between groups ($P = 0.663$) [16].

In our study, according to modified Odom's criteria functional outcome at 12 months of follow-up excellent grade found in 18 patients (90%) and good grade found in 2 patients (10%) in standalone PEEK cage group and excellent grade found in 17 patients (85%) and good grade found in 3 patients (15%) in tricortical ICG with plate group. There was no statistically significant difference between the two groups. Ayman et al. 2013 stated in their study that according to Odom criteria, 18/20 patients (90%) were graded excellent – good in the cage group compared to 16/20 patients (85%) in the group with bone graft. No patients as graded poor. Islam et al. 2016 stated that according to Odom criteria, they graded 14 patients (93.3%) excellent-good in the cage group in comparison to 13 patients (86.6%) in the bone graft group [7].

Conclusion

ACDF is the standard technique for the treatment of degenerative cervical disc disease. Excellent functional outcome and good fusion which could be achieved by either standalone PEEK cage or tricortical ICG with plate and there is no significant difference in the post-operative follow-up, fusion rate, clinical and functional outcomes between the standalone PEEK cage and tricortical ICG with plate groups.

References

1. Rao RD, Currier BL, Albert TG. Degenerative cervical Spondylosis clinical syndromes, pathogenesis, and management. *J Bone Joint Surg* 2007;89:1360-78.
2. Waltz TA. Physical factors in the production of the myelopathy of cervical spondylosis. *Brain* 1967;90:395-404.
3. Robinson RA, Afeiche N, Dunn EJ, Northrup BE. Cervical spondylotic myelopathy, etiology and treatment concepts. *Spine* 1977;2:89-99.
4. Bohlman HH, Emery SE, Goodfellow DB, Jones PK. Robinson anterior cervical discectomy and arthrodesis for cervical radiculopathy. Long-term follow-up of one hundred and twenty-two patients. *J Bone Joint Surg* 1993;75:1298-307.
5. Wilkinson M. The morbid anatomy of cervical spondylosis and myelopathy. *Brain* 1960;83:589-616.
6. Spallone A, Marchione P. Anterior cervical discectomy and fusion with "mini-invasive" harvesting of iliac crest graft versus polyetheretherketone (PEEK) cages: A retrospective outcome analysis. *Int J Surg* 2014;12:1328-32.
7. Islam MA, Rana MM, Goni MF, Rahman MN. Comparison between anterior cervical discectomy with fusion by polyetheretherketone cages and tricortical iliac crest graft for the treatment of cervical prolapsed intervertebral disc. *Bangabandhu Sheikh Mujib Med Univ J* 2016;9:169-72.
8. Sharma A, Kishore H. Comparative study of functional outcome of anterior cervical decompression and interbody fusion with tricortical stand alone iliac crest autograft versus stand-alone polyetheretherketone cage in cervical spondylotic myelopathy. *Glob Spine J* 2018;8:860-5.
9. Siddiqui AA, Jackowski A. Cage versus tricortical graft for cervical interbody fusion. *J Bone Joint Surg Br* 2003;85:1019-25.
10. Lee JC, Jang HD, Ahn J, Choi SW, Kang D, Shin BJ. Comparison of cortical ring allograft and plate fixation with autologous iliac bone graft for anterior cervical discectomy and fusion. *Asian Spine J* 2019;13:258-64.
11. Adam FF, Hasan KM, Meshtaway EM, Refae EH. PEEK cages versus locked plate for multiple levels cervical degenerated disease. *J Am Sci* 2013;9:100-6.
12. Islam MA, Habib MA, Sakeb N. Anterior cervical discectomy, fusion and stabilization by plate and screw early experience. *Bangladesh Med Res Council Bull* 2012;38:62-6.
13. Abdallah A, Taha AM. Cages or plates for anterior interbody fusion for cervical radiculopathy: Single and double levels. *Egypt Orthop J* 2016;51:65-70.
14. Ayman EA, Galhom MD. Comparison between polyetheretherketone cages versus an iliac crest autograft used in treatment of single or double level anterior cervical discectomy. *Med J Cairo Univ* 2013;81:9-17.
15. Shao MH, Zhang F, Xu HC, Lyu FZ. Titanium cages versus autogenous iliac crest bone grafts in anterior cervical discectomy and fusion treatment of patients with cervical degenerative diseases: A systematic review and meta-analysis. *Curr Med Res Opin* 2017;33:803-11.
16. Smith GW, Robinson RA. The treatment of certain cervical-spine disorders by anterior removal of the intervertebral disc and interbody fusion. *J Bone Joint Surg Am* 1958;40:607-24.

Declaration of patient consent: The authors certify that they have obtained all appropriate patient consent forms. In the form, the patient has given his consent for his images and other clinical information to be reported in the Journal. The patient understands that his name and initials will not be published, and due efforts will be made to conceal his identity, but anonymity cannot be guaranteed.

Conflict of Interest: NIL
Source of Support: NIL

How to Cite this Article

Islam MA, Shohidullah M, Islam R, Islam AI, Chowdhury AZ | Comparative Study between Anterior Cervical Discectomy and Fusion by Standalone Polyetheretherketone Cages and Tricortical Bone Graft with Anterior Plate Fixation for Cervical Spondylotic Myeloradiculopathy | *Back Bone: The Spine Journal* | October 2021-March 2022; 2(2): 79-83.