Case Report
Back Bone: The Spine Journal | October2021-March2022; 2(2): 93-97

Periosteal Variety of Sacral Osteoid Osteoma Encroaching into the Spinal Canal – Treatment with a Tubular Retractor System: Case Report

Ravish Patel[1], Shivam Shah[1], Naresh Kumar[2], Shammi Patel[3]

Abstract

Background: Osteoid osteomas are benign primary bone tumors with a predilection for posterior elements of the spinal column. Complete surgical excision through a traditional open approach is the treatment of choice for patients not responding to non-steroidal anti-inflammatory medications and patients with contraindications for nidus ablation. The study aims to highlight an alternative minimally invasive technique for complete surgical excision of osteoid osteoma encroaching into the spinal canal.

Methods: We report a case of 22 years-old obese male suffering from left S1 radiculopathy and night pain. Magnetic resonance imaging and computed tomography (CT)-scan of the lumbosacral region revealed a benign bony lesion of size 13 mm × 11 mm × 8 mm encroaching from S1 lamina into the spinal canal and compressing left S1 root. Peri-lesional bony sclerosis and soft tissue edema were absent. In view of obesity and a small size of the lesion, it was decided to remove the lesion with a tubular retractor system under general anesthesia. Complete resection of the lesion was carried out sparing the L5-S1 facet, with a minimally invasive approach.

Results: Patient had complete symptomatic improvement after the surgery. Histopathology showed interconnected trabeculae of woven bone matrix rimmed by osteoclasts consistent with the diagnosis of osteoid osteoma. Post-operative CT scan showed that the nidus was removed completely and important structures such as facet, pedicle, and midline posterior ligament complex were preserved. The patient resumed his daily activities and remained symptoms-free at the end of 6 months of follow-up.

Conclusion: Minimally invasive surgery using a tubular retractor system can be safe and effective alternative to traditional open surgery for excision of osteoid osteoma from the posterior elements. Faster recovery, minimal tissue damage, and early return to work are added advantages for an obese patient undergoing minimally invasive total surgical excision.

Keywords: Benign bone tumors, Sacral spine, Osteoid osteoma, Periosteal osteoid osteoma, Minimally invasive spine surgery, Tubular retractor system

Introduction

Osteoid osteomas (OO) are benign primary tumors of long bones with an incidence of 10–25% in the vertebral column [1, 2, 3]. Posterior elements are commonly involved (68–100%) with pars interarticularis as the most common site followed by lamina and pedicles [1]. The most common region involved is the lumbar spine (34–60%) followed by the cervical spine, thoracic spine, and least commonly involved is the sacrum [1, 2, 3]. OO is commonly seen in the second and third decade of life with a male preponderance [3]. The most common presentation is pain that is worse at night and relieved with non-steroidal anti-inflammatory drugs (NSAIDs) [4, 5]. Patient can also present with a radiculopathy, painful scoliosis, and rarely neurological deficit [4, 5]. Histologically OO is characterized by immature woven bone and a vascularized stroma [2]. The treatment options include surgical excision, drilling, radiofrequency ablation, cryoablation, laser photocoagulation, and conservative treatment with NSAIDs [6, 7, 8, 9, 10, 11, 12, 13]. Surgical excision can be done by traditional open technique or by minimally invasive techniques [14, 15, 16].

Minimally invasive spine surgical (MISS) techniques have gained wide popularity over the past two decades and are



[1]Department of Orthopaedic Surgery, Sunshine Global Hospital, Vadodara, Gujarat, India.
[2]Department of Orthopaedic Surgery, National University Hospital, Singapore.
[3]Department of Orthopaedic Surgery, Krupa Orthopaedic Hospital, Surat, Gujarat, India.
Address of correspondence :
Dr. Ravish Patel,
Consultant Spine Surgeon, Sunshine Global Hospital, Vadodara, Gujarat, India.
E-mail: ravishspine@gmail.com

Submitted: 27/10/2020; Reviewed: 14/12/2020; Accepted: 5/7/2021; Published: 10/10/2021

Back Bone: The Spine Journal (The Official Journal Of "Spine Association of Gujarat") | Available on www.backbonejournal.com | DOI:10.13107/bbj.2022.v02i02.028

commonly used for degenerative and traumatic pathologies [17, 18]. Lately, MISS have been found to be feasible for the excision of small primary bone tumors, extradural and intradural tumors [14, 17, 18]. These techniques have given comparable outcomes to that of open surgery, but with advantages of less tissue damage, minimal blood loss, and shorter hospital stay [15, 17, 18, 19].

We report a case of OO of S1 lamina that was encroaching into the spinal canal and compressing on the S1 nerve root. As nidus ablation was contraindicated, the tumor was completely excised with a minimally invasive technique.

Materials and Methods

A 22-year-old obese male student presented with a history of worsening back pain for the past 6 months. His back pain typically aggravated at night and got relieved with non-steroidal anti-inflammatory drugs. For the past 3 months he also developed left lower limb radiculopathy with pain along S1 dermatomal distribution. The radiculopathy was associated with paraesthesia but no sphincter dysfunction was observed. There were no constitutional symptoms and the past history was not relevant except for frequent mechanical lower backaches. On examination, there was a severe limitation of spinal flexion movement due to pain. However, there was no paraspinal muscle spasm or spinal tenderness. Examination of root tension signs revealed a positive straight leg raise test at an angle of 45° and a positive Lasegue's test. Neurological examination was normal. Conventional radiographs did not show any abnormality other than mild reduction in the disc space at L5-S1. Magnetic resonance imaging (MRI) scan showed a benign lesion in the S1 lamina encroaching into the spinal canal and compressing the left S1 nerve roots (Fig. 1). The lesion was hypointense on T1 and T2 weighted images. There was no perilesional bony sclerosis or soft tissue edema around the lesion. Computed tomography (CT) showed an osseous lesion on the undersurface of the S1 lamina measuring 13 mm × 11 mm × 8 mm in size (Fig. 2). A presumed diagnosis of osteoid osteoma was made based on the clinical features and radiological findings. The other differentials that were ruled out after clinic-radiological evaluation were osteoblastoma (due to size <1.5 cm), periosteal chondroma (very rare occurrence), aneurysmal bone cyst (no cyst formation), and sequestrated calcified disc [20].

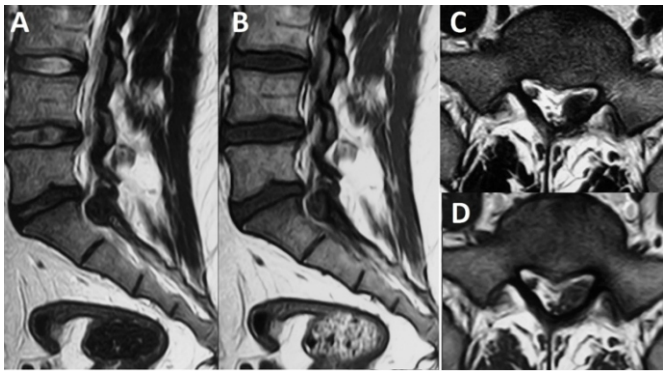

Figure 1: Pre-operative magnetic resonance imaging showing benign tumor attached to S1 lamina and encroaching into the spinal canal in parasagittal T2W image (a) and T1W image (b). Compression on the left S1 nerve root is seen in axial T2W image (c) and T1W image (d).

Figure 2: Pre-operative computed tomography scan showing benign bone lesion without any periosteal reaction in sagittal (a), coronal (b), and axial (c) sections.

Figure 3: Sequential dilatation through tubes (a) showing 7 centimeters depth of S1 lamina from the dermis. Primary surgical wound (b) after tubular retractor assisted excision of osteoid osteoma. The excised tumor mass (c) is seen attached to removed S1 laminar fragment.

We decided to perform total excision of the lesion with a microendoscopic tubular retractor system. Under general anesthesia, patient was placed in a prone position on horizontal bolsters. After routine painting and draping, a longitudinal skin incision of size 2.5 cms was made 1.5 cms to the left from the midline at the level of the L5-S1 joint. After fasciotomy, fluoroscopy-guided docking of serial dilators was carried out on the upper edge of S1 lamina in order to bluntly split the paraspinal muscles (Fig. 3). A 22 mm expandable tube (Metrix, Medtronic Sofamor Danek, Memphis, TN, USA) was used for the surgery and the flanges of the tube that can be expanded to 30 mm were centered on the S1 lamina. Final positioning was confirmed with fluoroscopy. Under microscopic visualization, L5-S1 left laminoforaminotomy and flavectomy done to identify the S1 root and the dural sac. Care was taken to avoid L5-S1 facet joint violation. The bony roof of the S1 foramen was removed with a burr along the S1 nerve root. This formed the lateral limit of resection of the lamina. The base of the S1 spinous process was burred and a 2-mm Kerrison rounger was used to separate the medial edge of the lamina from the base of the spinous process. Based on preoperative CT measurements, the inferior edge of the resection was determined to be about 2 cms below the superior edge of the lamina. A cut portion of sterile plastic scale was placed on the lamina and visualized under the microscope to determine accurately the inferior edge of resection. The resection was complete, the mass was detached from all four sides and removed through the tube (Fig. 3). Around 2–3 mm of additional laminar bone was removed with Kerrison in order to ensure no residual or marginal tumor was left behind. The inflamed S1 nerve root was completely free at the end of the resection. The lesion resected was sent for histopathological confirmation.

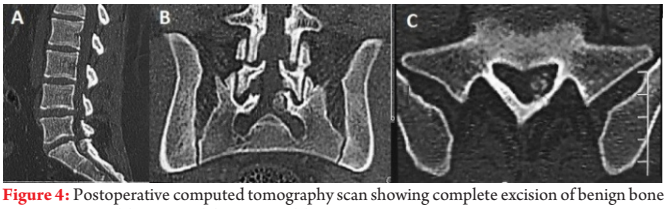

Figure 4: Postoperative computed tomography scan showing complete excision of benign bone lesion in sagittal (a), coronal (b), and axial (c) sections.

Results

The surgical duration was 120 min and the blood loss was 50 mL. Immediately after surgery, S1 radicular pain reduced significantly. Patient was able to walk on the same day evening and was discharged the next day. Mild postoperative back pain got better over the next 5–7 days. No surgery-related complications were observed. A post-operative CT scan showed that the lesion was excised completely and the left L5-S1 joint remained intact (Fig. 4). Histopathology confirmed complete excision and showed interconnected trabeculae of woven bone rimmed with osteoclasts and separated by a fibrovascular stroma. Patient resumed full activities after 7 days and remained asymptomatic at the end of 6 months of follow-up.

Discussion

OO is difficult to visualize on plain radiographs and hence are frequently misdiagnosed or diagnosed late in up to 54% of patients [4, 11]. OOs are often confused with inflammatory synovitis, idiopathic scoliosis, tuberculosis, and spondylolysis [11]. The classical findings on MRI include perilesional bony sclerosis and soft tissue edema around the nidus [21]. However, it is worthwhile to note that the periosteal reaction or sclerosis surrounding the lesion is typical of the cortical variety of osteoid osteoma while it may be absent in medullary and periosteal (juxtacortical) varieties of spinal OO as observed in our case [6]. Hence a thin-slice CT-scan is considered the investigation of choice and the presence of a nidus is considered the gold standard for identification of osteoid osteoma [6, 22]. Osteoblastoma is another large primary benign bone tumor that shows similar histological characteristics as that of osteoid osteoma. The only distinction between the two is the size of the tumor. When the maximum diameter of tumor is <1.5 cms it is labeled as osteoid osteoma while lesions more than 1.5 cms are considered osteoblastomas [23].

The treatment options for osteoid osteoma of the spine include medical management, radiofrequency ablation or cryoablation, and intralesional/enbloc total excision [6, 8, 13]. Medical management is reserved only for patients unwilling to undergo any intervention due to the fact that osteoid osteoma takes 2–5 years to regress and the patient may be subjected to severe pain and prolonged use of NSAIDs during the treatment tenure [9, 24]. Radiofrequency ablation is a safe and effective minimally invasive alternative for the treatment of OO with a success rate of 76–100% and a concomitant biopsy can also be obtained [8]. The most adverse complication of the technique is injury to adjacent neurovascular structures. Although epidural insufflation of air and neuromonitoring can help to avoid neural injury, it is advisable to perform ablation only when there is more than 1 mm of CSF signal between the lesion and the neural structure [8]. Alternatively, an intact cortical bony layer between the lesion and neural tissue is required [8]. Both the conditions were not fulfilled in our case hence radiofrequency ablation was not considered. Laser photocoagulation is a cost-effective alternative that has several advantages over radiofrequency ablation. It can be performed through a smaller needle and is feasible even in patients with pacemakers, stimulators, and metallic structures. However, passive insulation, air cooling, and thermal monitoring are required when the distance between neural structure and nidus is less than 8–10 mm or there is the absence of thick cortical layer between the two [12]. Cryoablation is another minimal invasive modality for the treatment of OO with minimal post-procedural pain and provides visual control during the procedure but high cost and lack of the safe distance between the probe and the neural tissue precluded its use in the current case [13]. Thus when nidus ablation is contraindicated surgical resection remains the mainstay of OOs. According to Enneking staging of benign tumors, OO is latent or locally active tumor and can be treated by drilling, intralesional piecemeal resection, or marginal excision [11]. The lesion should be identified with a fluoroscopy-guided landmarks or a CT-based navigation. Once identified, complete removal of the nidus without causing damage to adjacent uninvolved tissues (facets, pedicles) is the goal of OO surgery. The success rate varies from 80% to 98% with recurrence rate reported in the range of 2–5% and instability or fusion reported in the range of 20–50% between different studies [1, 2]. Despite favorable results of open techniques, it requires wide stripping of paraspinal muscles and a wide laminectomy. This can translate into significant blood loss, corset immobilization, prolonged hospitalization, and slow return to normal activities of daily living [17, 18]. Hence, MISS techniques using tubular retractor system and endoscopes are increasingly used to overcome the approach-related issues [14, 16, 18].

The advantages of the MISS technique were particularly relevant for our patient due to obesity, young age, and location of tumor. In an obese patient, open surgery requires wider exposure, more soft tissue dissection, and tissue damage. Thus MISS technique would give better perioperative results compared to equivocal open surgery. In our case report, the proximity of the lesion to the S1 nerve root precluded the use of

radiofrequency, laser photocoagulation, or cryoablation (Fig. 1). We preferred to use the tubes as tubular retractor systems have been traditionally used for the excision of benign tumors of the spine [14, 17, 18]. Since the size of tumor was about 2/3rd of the diameter of the tube it can be excised enbloc using a 22 mm expandable tube (Medtronics). Moreover, the posterior location of the tumor in the lamina was favorable for excision of the lesion and non-fusion surgery.

Limitation of MISS techniques must be considered before planning a tumor excision. Orientation difficulties, incorrect positioning, and risk of incomplete resection are some of the commonly faced technical challenges [18]. Preoperative CT-based planning is absolutely essential and an intra-operative navigation if available can help overcome the potential problem of incomplete resection. It is important to note that these MISS techniques are better avoided in cases with suspected malignancy and highly vascular tumors (risk of hemorrhage). Along with these considerations, the learning curve and surgeon's expertise should be factored before considering the MISS technique for tumor excision.

Conclusion

Our case report demonstrates that minimally invasive surgery using a tubular retractor system can be safe and effectively alternative to traditional open surgery for excision of osteoid osteoma from the posterior elements. Faster recovery, minimal tissue damage, and early return to work are advantages relevant for an obese patient undergoing primary tumor excision. Case series or long-term perspective studies are required to further determine the feasibility of total resection in different locations of the spine, recurrence rate, and maintenance of spinal stability.

Clinical Relevance

OO occurring in posterior elements of the spine are frequently misdiagnosed. Thin slice CT-scan is the investigation of choice for the diagnosis of osteoid osteoma. Few select cases of osteoid osteoma can be excised with a minimal invasive tubular retractor system.

References

1. Gasbarrini A, Cappuccio M, Bandiera S, Amendola L, van Urk P, Boriani S. Osteoid osteoma of the mobile spine: Surgical outcomes in 81 patients. Spine (Phila Pa 1976) 2011;36:2089-93.
2. Jackson RP, Reckling FW, Mants FA. Osteoid osteoma and osteoblastoma. Similar histologic lesions with different natural histories. Clin Orthop Relat Res 1977;128:303-13.
3. Janin Y, Epstein JA, Carras R, Khan A. Osteoid osteomas and osteoblastomas of the spine. Neurosurgery 1981;8:31-8.
4. Kirwan EO, Hutton PA, Pozo JL, Ransford AO. Osteoid osteoma and benign osteoblastoma of the spine. Clinical presentation and treatment. J Bone Joint Surg Br 1984;66:21-6.
5. Zileli M, Cagli S, Basdemir G, Ersahin Y. Osteoid osteomas and osteoblastomas of the spine. Neurosurg Focus 2003;15:E5.
6. Noordin S, Allana S, Hilal K, Nadeem N, Lakdawala R, Sadruddin A, et al. Osteoid osteoma: Contemporary management. Orthop Rev (Pavia) 2018;10:7496.
7. Kadhim M, Binitie O, O'Toole P, Grigoriou E, De Mattos CB, Dormans JP. Surgical resection of osteoid osteoma and osteoblastoma of the spine. J Pediatr Orthop B 2017;26:362-9.
8. Albisinni U, Facchini G, Spinnato P, Gasbarrini A, Bazzocchi A. Spinal osteoid osteoma: Efficacy and safety of radiofrequency ablation. Skeletal Radiol 2017;46:1087-94.
9. Kneisl JS, Simon MA. Medical management compared with operative treatment for osteoid-osteoma. J Bone Joint Surg Am 1992;74:179-85.
10. Etemadifar MR, Hadi A. Clinical findings and results of surgical resection in 19 cases of spinal osteoid osteoma. Asian Spine J 2015;9:386-93.
11. Pourfeizi HH, Tabrizi A, Bazavar M, Sales JG. Clinical findings and results of surgical resection of thoracolumbar osteoid osteoma. Asian Spine J 2014;8:150-5.
12. Tsoumakidou G, Thenint MA, Garnon J, Buy X, Steib JP, Gangi A. Percutaneous image-guided laser photocoagulation of spinal osteoid osteoma: A single-institution series. Radiology 2016;278:936-43.
13. Santiago E, Pauly V, Brun G, Guenoun D, Champsaur P, Le Corroller T. Percutaneous cryoablation for the treatment of osteoid osteoma in the adult population. Eur Radiol 2018;28:2336-44.
14. Nzokou A, Weil AG, Shedid D. Minimally invasive removal of thoracic and lumbar spinal tumors using a nonexpandable tubular retractor. J Neurosurg Spine 2013;19:708-15.
15. Nakamura Y, Yabuki S, Kikuchi S, Konno S. Minimally invasive surgery for osteoid osteoma of the cervical spine using microendoscopic discectomy system. Asian Spine J 2013;7:143-7.
16. Xie T, Xiu P, Song Y, Zeng J, Huang S. Percutaneous endoscopic excision and ablation of osteoid osteoma of the lumbar spine and sacrum: A technical note and outcomes. World Neurosurg 2020;133:121-6.
17. Kim CW, Siemionow K, Anderson DG, Phillips FM. The current state of minimally invasive spine surgery. Instr Course Lect 2011;60:353-70.
18. Kim YB, Hyun SJ. Clinical applications of the tubular retractor on spinal disorders. J Korean Neurosurg Soc 2007;42:245-50.
19. Hikata T, Fujita N, Iwanami A, Watanabe K, Nakamura M, Matsumoto M, et al. Remodeling of the cervical facet joint after minimally invasive microendoscopic resection for cervical osteoid osteoma. Spine (Phila Pa 1976) 2016;41:E1191-4.
20. Jeong DM, Paeng SH. Enchondroma of the cervical spine in young woman: A rare case report. Asian J Neurosurg 2015;10:334-7.
21. Harish S, Saifuddin A. Imaging features of spinal osteoid osteoma with emphasis on MRI findings. Eur Radiol 2005;15:2396-403.
22. Gamba JL, Martinez S, Apple J, Harrelson JM, Nunley JA. Computed tomography of axial skeletal osteoid osteomas. AJR Am J Roentgenol

1984;142:769-72.

23. Barlow E, Davies AM, Cool WP, Barlow D, Mangham DC. Osteoid osteoma and osteoblastoma: Novel histological and immunohistochemical observations as evidence for a single entity. J Clin Pathol 2013;66:768-74.

24. Ilyas I, Younge DA. Medical management of osteoid osteoma. Can J Surg 2002;45:435-7.

Declaration of patient consent: The authors certify that they have obtained all appropriate patient consent forms. In the form, the patient has given his consent for his images and other clinical information to be reported in the Journal. The patient understands that his name and initials will not be published, and due efforts will be made to conceal his identity, but anonymity cannot be guaranteed.

Conflict of Interest: NIL
Source of Support: NIL

How to Cite this Article

Patel R, Shah S, Kumar N, Patel S | Periosteal Variety of Sacral Osteoid Osteoma Encroaching into the Spinal Canal – Treatment with a Tubular Retractor System: Case Report | Back Bone: The Spine Journal | October 2021-March 2022; 2(2): 93-97.