Original Article
Back Bone: The Spine Journal | October2021-March2022; 2(2): 60-64

Minimally Invasive Trans-foraminal Lumbar Interbody Fusion (MI-TLIF): Technique, Tips and Tricks

Sanjeev Asati[1], Saijyot Raut[1], Vishal Kundnani[1], Amit Chugh[1], Ameya Rangekar[1], Praveen VNR Goparaju[1]

Abstract

Surgical interbody fusion is the main stay of treatment in many lumbar pathologies. Of these, transforaminal lumbar interbody fusion has progressively gained popularity among fusions due to its safety and satisfactory results. With the ever-ending evolution of technological advancements enabled spine surgeons to embrace minimally invasive surgeries mainly due to focal nature of the pathology. Tubular retractors have been tried and tested with very good results when used with microscopic magnification. They helps in surgical decompression and fusion through transforaminal approach with minimal footprint and have proven their versatility by delivering excellent outcomes. Near total bloodless surgery, better cosmesis, decreased hospital stay, lower pain score, early return to work, are some other proven advantages with minimally invasive transforaminal interbody fusion MIS-TLIF. However, high procedural costs and longer trajectory of learning is restraining many surgeons from adapting this technique over time tested open procedures. In this report the authors discuss about the nuances of the surgical procedure, tips and tricks to provide a comprehensive insight and better understanding.

Keywords: MIS-TLIF, Minimally invasive spine surgery, Transforaminal lumbar interbody fusion.

Introduction

Lumbar interbody fusion for degenerative lumbar spine pathology is a well-known procedure. Several different techniques are available for spinal arthrodesis with their inherent benefits and disadvantages. [1, 2] TLIF which is a trans-foraminal approach (instead of translaminar approach of PLIF) has rapidly gained popularity, since 1998 when Harms first reported his results. [3] It was reported as safe, without any potential complications described when using combined anterior-posterior fusion and PLIF techniques. Surrounding muscle damage followed by muscle atrophy and loss of function is hughest while using the posterior midline approach. Any procedure that is less invasive than open surgery while being used for the same purpose refers to as minimally invasive surgery. Foley et al introduced MISTLIF in early 2000s utilizing tubular retractors via a muscle-splitting approach, thus decreasing iatrogenic injury to the muscle and soft tissues.[4] Since the time of its inception, it was documented with fewer complications, , shorter hospital stay, lesser blood loss and faster recovery, with similar clinical and radiological outcomes compared with open TLIF.[5-9] Studies have found profound inter and intramuscular edema in the MRI images of patients operated with open TLIF at 6 months as compared to the normal appearance in patients with MIS-TLIF.[12] Kim et al. [10] found that, there is 2–7-fold increase in skeletal muscle damage, in patients who were operated with open TLIF as compared to MIS TLIF. One more finding in the study is that the extension strength has been improved by 50%, compared to open technique. [11] As compared to open TLIF, minimally invasive TLIF entails disadvantages like longer surgical time and long learning curve. The purpose of this manuscript is to describe MIS-TLIF technique, its advantages and to provide tips and tricks related to the procedure.



[1]Department of Spine Surgery, Bombay Hospital & Medical Research Centre, Mumbai, Maharashtra, India.
[2]Mumbai Spine Scoliosis and Disc Replacement Centre, Mumbai, Maharashtra, India.

Address of correspondence :
Dr. Saijyot Raut,
Clinical spine fellow, Bombay Hospital & Medical Research Centre & Mumbai Spine Scoliosis and Disc Replacement Centre, Mumbai, Maharashtra, India.
E-mail: saijyotraut@gmail.com

Indications

Surgical indications for MIS-TLIF are similar to open TLIF.

1. Degenerative disc disease
2. Lumbar segmental instability (degenerative, iatrogenic or other causes)

Submitted: 27/4/2021; Reviewed: 10/6/2021; Accepted: 15/9/2021; Published: 10/10/2021

Back Bone: The Spine Journal (The Official Journal Of "Spine Association of Gujarat") | Available on www.backbonejournal.com | DOI:10.13107/bbj.2022.v02i02.022

Figure 1: A 3 cm long paraspinal incision 3–4 cm away from midline for decompression utilizing the same for pedicle screw insertion on that side And two small incisions of around 2 cms each for pedicle screw insertion.

Figure 2: The tubular retractor is passed over the dilators and docked over the facet and spino-laminar line.

3. Spondylolisthesis
4. Degenerative scoliosis
5. Spinal stenosis with instability
6. Recurrent disc herniation
7. Spondylodiscitis

Contraindications

1. Multilevel disease with severe facetal arthropathies.
2. Poor fluoroscopic visualization of the Bony anatomy.
3. Non-availability of MIS instruments.
4. Conjoint nerve in foramen.

Operative technique

➢ Positioning: Patient in prone position on horizontal or vertical bolsters with hip and knee kept flexed on radiolucent table. Important points to be kept in mind while positioning the patient are:

- Eye care: ophthalmic ointment, avoid pressure over eyes.
- Rule out hip joint and shoulder contracture.
- Head end elevation of the bed to reduce facial pressure and swelling.
- Abdomen to be kept free from compression.
- All bony prominences are padded especially ASIS, knee, ankle
- Padding of axilla and elbow to avoid peripheral nerve compression.

➢ About 3 cm long incision is to be taken paraspinally, 3-4 cm away from midline. The incision is taken on the more symptomatic side. (Figure 1)

➢ Under fluoroscopic guidance, first dilator is directed in a lateral to medial trajectory, towards the facet joint.

➢ With serial dilatation with dilatores, a muscle-splitting surgical channel is created. The appropriate-length tubular retractor is inserted and docked over the spino-laminar and facet joint line. (Figure 2)

➢ The flexible articulated arm connects the retractor to the table and confirmed under flouroscopy. The remainder of the procedure is performed using an operating microscope.

➢ The soft tissue over the dorsal surface of the facet complex is electrocauterised and removed using pituitary forceps.

➢ A total facetectomy is done either using, rongeurs, high-speed burr or osteotomes. An initial step is to disarticulate the inferior facet from the superior lamina. It is then separated from the ligamentum flavum and the synovial membrane using ronguers or curettes and pituitary forceps. Then, a pituitary forceps is used to remove the inferior facet in total. The remaining superior facet is to be removed using a Kerrison rongeur in piecemeal fashion.

➢ By morcellizing the removed bones, it can be used as bone graft later.

➢ A sleeve of intact synovial membrane and ligamentum flavum serves to protect the nerve roots and dura mater. The Kerrison rongeur is used remove the synovial membrane and ligamentum flavum piece by piece to expose the traversing and the exiting nerve roots. Thrombin-soaked Gelfoam and bipolar cautery is used to counter the epidural bleeding.

➢ Over the top decompression can be achieved by undercutting the spinous process and drilling the contralateral lamina in patients with bilateral symptoms and central stenosis.

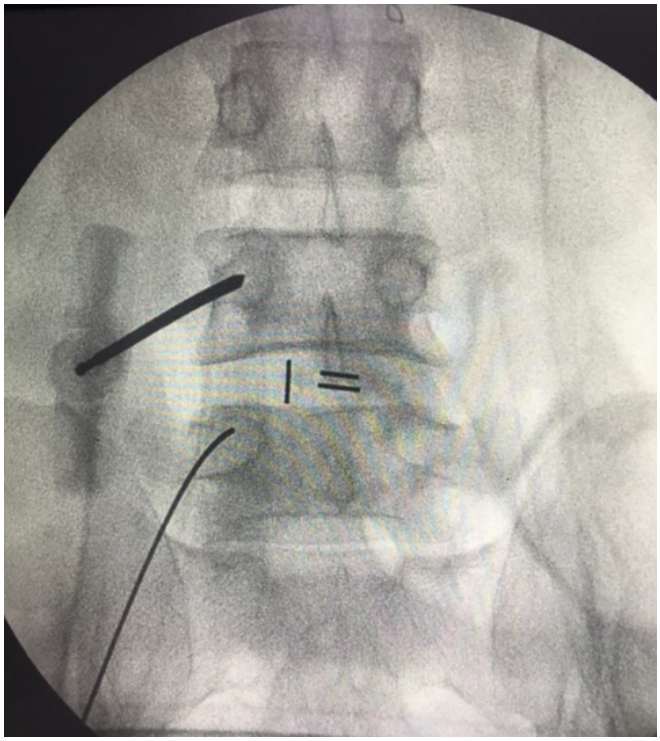

Figure 3: Picture showing tip of Jamshedi needle lies along the lateral border of pedi-cle at 9'O clock position and needle gently tapped further-always light to moderate taps.

➢ Disc space is identified and Traversing and exiting nerve roots are protected and pushed away using cotton patties.

➢ Disc annulus is incised carefully with a box cut incision and is removed using pituitary rongeurs. Scrappers and currettes are used for endplate preparation. All of the cartilaginous endplate is removed and thoroughly decorticated using reamers, various curettes. If required, neural retraction using nerve root retractor is placed over the traversing nerve root.

➢ Loose particles from disc space are cleared by extensive irrigation and rinsing and bone graft is inserted in anterior one third of the disc space. An appropriate sized cage filled with bone graft is inserted in disc space through working channel under fluoroscopy control.

➢ After the cage is placed, any neural compression is checked using the nerve hook

➢ After completion of interbody work and decompression, tubular retractor is removed.

➢ Percutaneous pedicle screw insertion: It mandates quality fluoroscopic images with optimal visualization of pedicle of desired vertebrae. True AP and lateral image of desired vertebral body should be obtained which shows Superior vertebral endplate as a single dense line and Spinous process centered between pedicles in AP view and Superior endplate as a single dense line and Posterior cortex single radio-opaque line in lateral view.

· Palpate the transverse process and Jamshedi needle is walked along it.

· Tip lies along the lateral border of pedicle at 3'o clock or 9'o clock position (Figure 3) and Needle gently tapped further-always light to moderate taps.

· At the pedicle isthmus on lateral view, AP view medial border of the pedicle should not be breached.

· Guide wire inserted over jamshidi needle.

· Jamshidi needle removed without pulling out guide wires inadvertently.

· Tapping done over guide wires: Important that the assistant holds the guide wire to prevent its anterior migration or pull out.

· Cannulated pedicle screws can be inserted over guide wires now.

· Rod length measured and inserted after at last.

➢ Percutaneous screws and a rod are then placed ipsilaterally through the same incision and contralateral percutaneous pedicle screws are inserted by taking a stab incision on the opposite side. Rods are inserted on both the sides and compressed to create some amount of lordosis as well as providing compression for the bone graft.

➢ Correct implant positioning is documented with Anteroposterior and lateral fluoroscopic imaging. Wound closure is done in layers.

Post-operative management

All the patients are mobilized on the same day in the evening and taught physiotherapy. Heavy weight lifting and forward bending is to be avoided for three weeks and regular follow-up (3 weeks, 3, 6 and 12 months) to be done for clinical and radiological assessment.

Complications

As with any other technique MIS TLIF has some inherent complications. The main notable ones are

· Dural tear
· Nerve root injury
· Visceral/ vascular injury
· Graft malposition
· Cage migration
· Pseudo-arthrosis
· Infection
· Screw malposition
· Guide wire breakage
· Wrong level surgery
· Inadequate decompression

Discussion

MIS-TLIF has significantly better peri-operative results in the form of lesser peri-operative blood loss, better cosmesis and shorter hospital stay than the open method. Most studies have reported favorable clinical outcomes with MIS-TLIF. Shunwu

et al. discovered significantly lower creatine kinase levels postoperatively, in MIS group [12]. Wang et al found through electrophysiology examination and MRI findings, that there is significant reduction of sacrospinalis muscle injury in the MIS group [13]. However, there are certain challenges like learning curve of MIS procedure, more surgical time, to treat bilateral symptoms though unilateral approach and more radiation associated with MIS-TLIF. Kim et al by using navigation-assisted MIS-TLIF, concluded that the use of navigation significantly reduced radiation exposure [14]. Navigation also decreases the fluoroscopy time during the insertion of pedicle screws [15]. In future, the navigation might hold key to minimize X-ray exposure to MIS surgeons.

The authors recommend certain guidelines to be followed during initial cases to reduce the learning curve of this technique and also to have tissue-training in mentoring programs and to practice them on bone saw bone models

1. Thorough knowledge on anatomy and its landmarks and proper pre-operative planning

a. Pedicle anatomy.

b. Anatomic landmarks include, spinous process (bifid/bulbous), laminar inclination, , facet joint orientations and tropism should be studied.

2. Appropriate selection of patients.

3. Proper positioning of patient.

4. True-AP/Lateral c-arm images are must before docking the tube and inserting the guidewires.

5. The laterality of the skin incision should be tailored based on the patients size and obesity.

6. An appropriate tubular retractor length is essential to avoid soft tissue herniation by using shorter and to avoid having longer working length by using longer tubes.

7. The appropriate tube diameter is again very important because, the larger tube even though broader vison and better performance, it may cause, impingement on to facet joint and spinous process causing soft tissue herniation in smaller patients.

8. Guide wire insertions should not precede, tube docking.

9. Start the first bite at spino-laminar junction and it should be the medial most point in your tube.

10. In initial cases, better to avoid burr to do laminotomy.

11. The incidence of dural tear can be reduced by keeping a layer of ligamentum flavum intact till facetectomy and bony decompression is completed.

12. Tactile feedback of the needle tip is important while inserting the pedicle screw, and try to palpate the bony junction between transverse process and lateral facet to select optimal entry point and get appropriate trajectory.

13. Never place a guide wire anterior to junction of anterior 1/3 and posterior 2/3 of the vertebral body.

14. To prevent the tulip of the screw from resting on facet joint, avoid driving the screws too much deeper than what is necessary.

15. For better eye-hand coordination, practice to handle the microscope on models.

Conclusion

MIS TLIF has significant proven advantages over other open methods of posterior interbody fusion techniques (TLIF or PLIF) in terms of lesser peri-operative bleeding, lesser hospital stay, better cosmesis, postoperative pain and functional outcomes. As with any other MIS techniques, MIS TLIF may result in steeper learning curves, though this is variable with training, experience and technique.

References

1. Stonecipher T, Wright S (1989) Posterior lumbar interbody fusion with facet screw fixation. Spine 14:468–47.
2. Fraser RD (1995) Interbody, posterior, and combined lumbar fusions. Spine 20:S167–S177.
3. Harms J, Jeszenszky D (1998) The unilateral transforaminal approach for posterior lumbar interbody fusion. Orthop Traumatol 6:88–99.
4. Foley KT, Holly LT, Schwender JD (2003) Minimally invasive lumbar fusion. Spine 15(suppl):26–35.
5. Jin-Tao Q, Yu T, MeiW, et al. Comparison of MIS vs. open PLIF/ TLIF with regard to clinical improvement, fusion rate, and incidence of major complication: a meta-analysis. Eur Spine J. 2015;24:1058-1065.
6. Khan NR, Clark AJ, Lee SL, Venable GT, Rossi NB, Foley KT. Surgical outcomes for minimally invasive vs open transforaminal lumbar interbody fusion: an updated systematic review and metaanalysis. Neurosurgery. 2015;77:847-874.
7. Adogwa O, Parker SL, Bydon A, Cheng J, McGirt MJ. Comparative effectiveness of minimally invasive versus open transforaminal lumbar interbody fusion: 2-year assessment of narcotic use, return to work, disability, and quality of life. J Spinal Disord Tech. 2011;24:479-484.
8. Gu G, Zhang H, Fan G, et al. Comparison of minimally invasive versus open transforaminal lumbar interbody fusion in two-level degenerative lumbar disease. Int Orthop. 2014;38:817-824.
9. Kulkarni AG, Patel RS, Dutta S. Does minimally invasive spine surgery minimize surgical site infections? Asian Spine J. 2016;10: 1000-1006.
10. Kim KT, Lee SH, Suk KS, Bae SC. The quantitative analysis of tissue injury markers after mini-open lumbar fusion. Spine (Phila Pa 1976) 2006;31:712-6.
11. Kim DY, Lee SH, Chung SK, Lee HY. Comparison of multifidus muscle atrophy and trunk extension muscle strength: Percutaneous versus open pedicle screw fixation. Spine (Phila Pa 1976) 2005;30:123-9.
12. Shunwu F, Xing Z, Fengdong Z, Xiangqian F (2010) Minimally invasive transforaminal lumbar interbody fusion for the treatment of degenerative lumbar diseases. Spine 35:1615–1620.
13. Wang HL, Lu FZ, Jiang JY, Ma X, Xia XL, Wang LX (2011) Minimally invasive lumbar interbody fusion via MAST Quadrant retractor versus open surgery: a prospective randomized clinical trial. Chin Med J (Engl) 124:3868–3874.
14. Kim CW, Lee YP, Taylor W, Oygar A, Kim WK (2008) Use of navigation-assisted fluoroscopy to decrease radiation exposure during minimally invasive spine surgery. Spine J 8:584–590.
15. Tjardes T, Shafizadeh S, Rixen D, Paffrath T, Bouillon B, Steinhausen ES, Baethis H (2010) Image-guided spine surgery: state of the art and future directions. Eur Spine J 19:25–45/

Declaration of patient consent: The authors certify that they have obtained all appropriate patient consent forms. In the form, the patient has given his consent for his images and other clinical information to be reported in the Journal. The patient understands that his name and initials will not be published, and due efforts will be made to conceal his identity, but anonymity cannot be guaranteed.

Conflict of Interest: NIL
Source of Support: NIL

How to Cite this Article

Asati S, Raut S, Kundnani V, Chugh A, Rangekar A, Goparaju P VNR | Minimally Invasive Transforaminal Lumbar Interbody Fusion (MI-TLIF): Technique, Tips and Tricks | Back Bone: The Spine Journal | October 2021-March 2022; 2(2): 60-64.